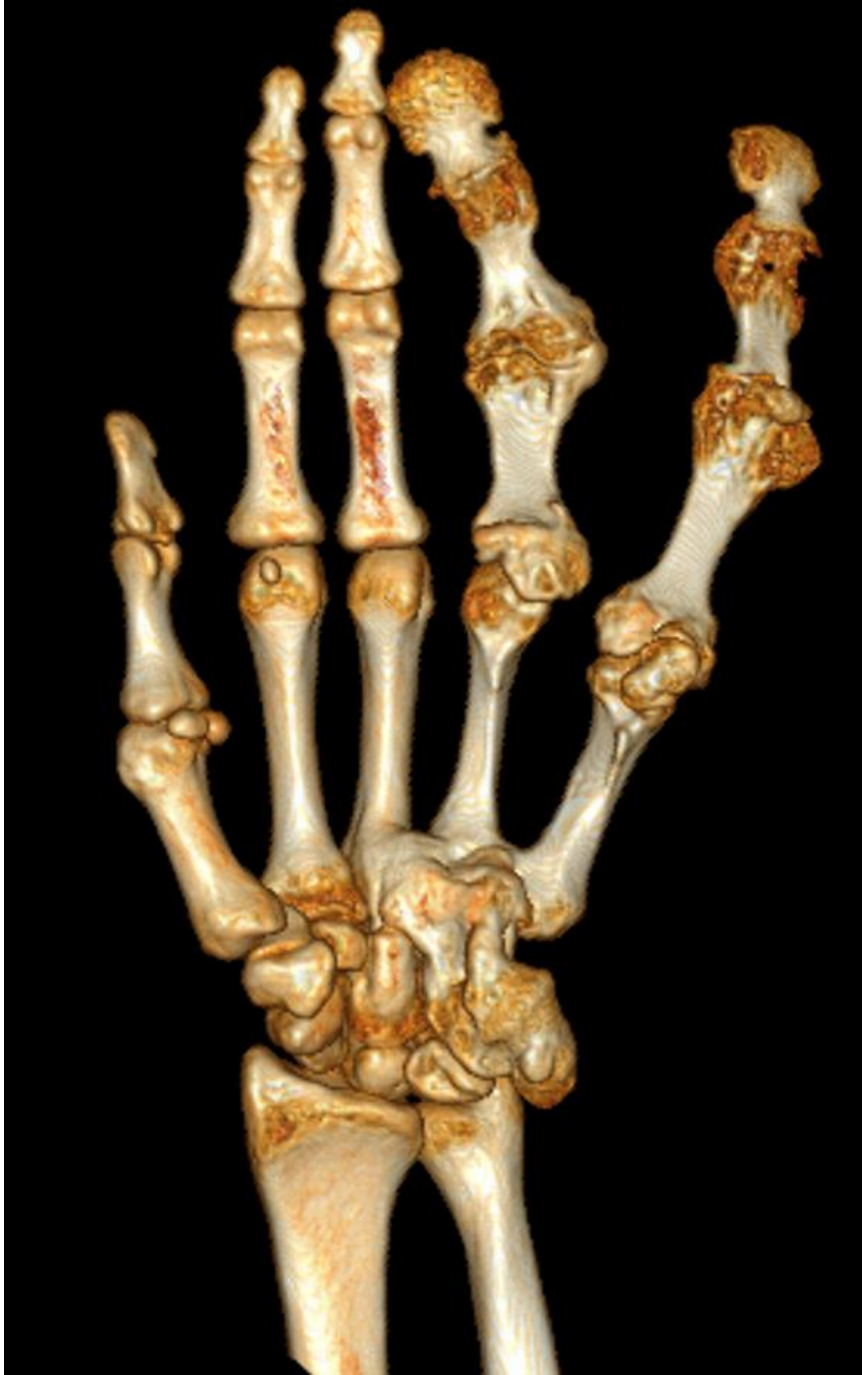
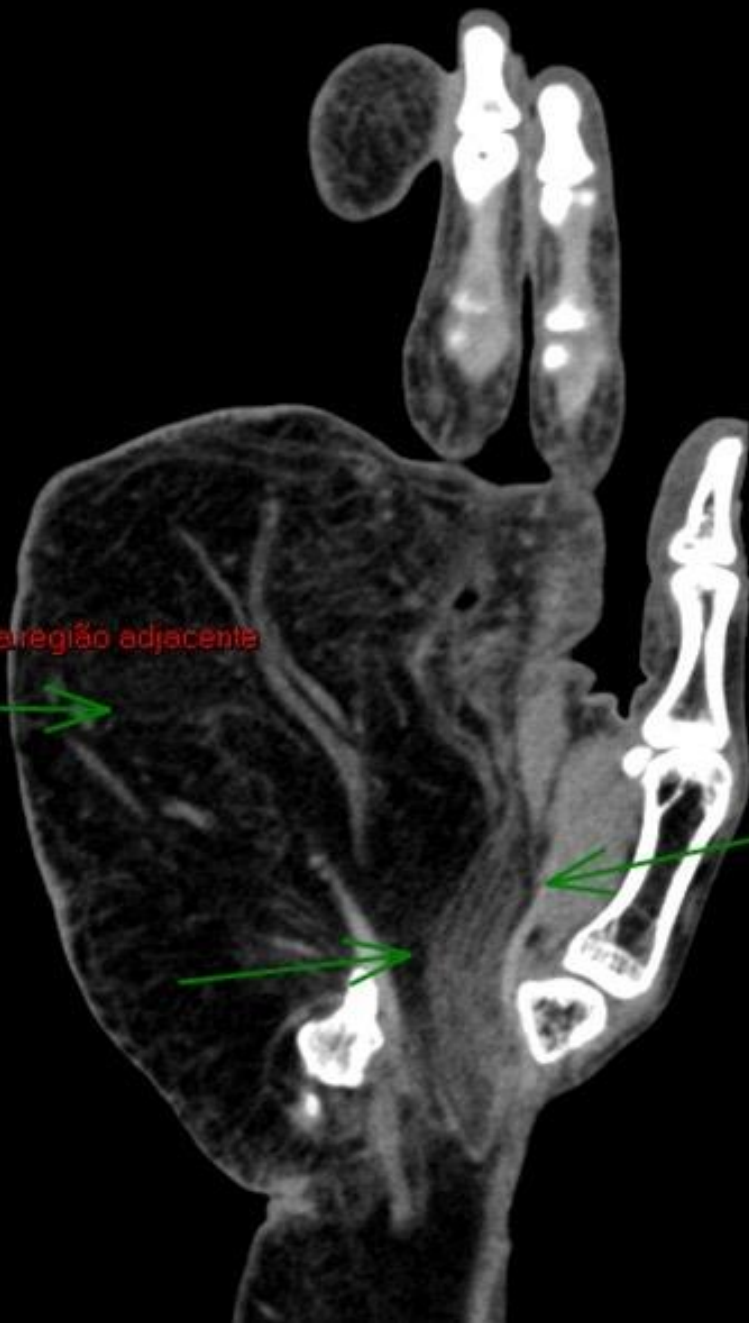
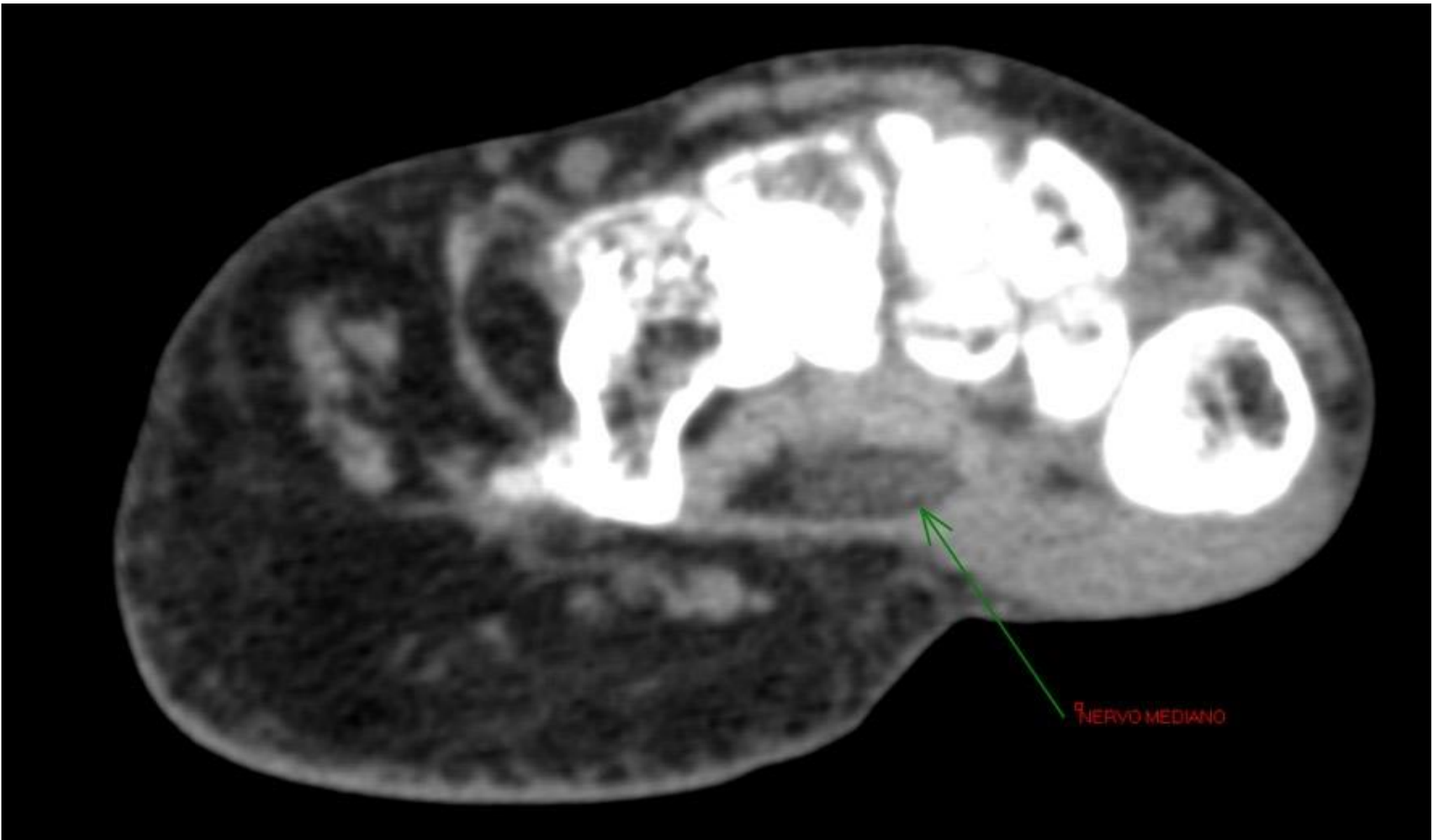


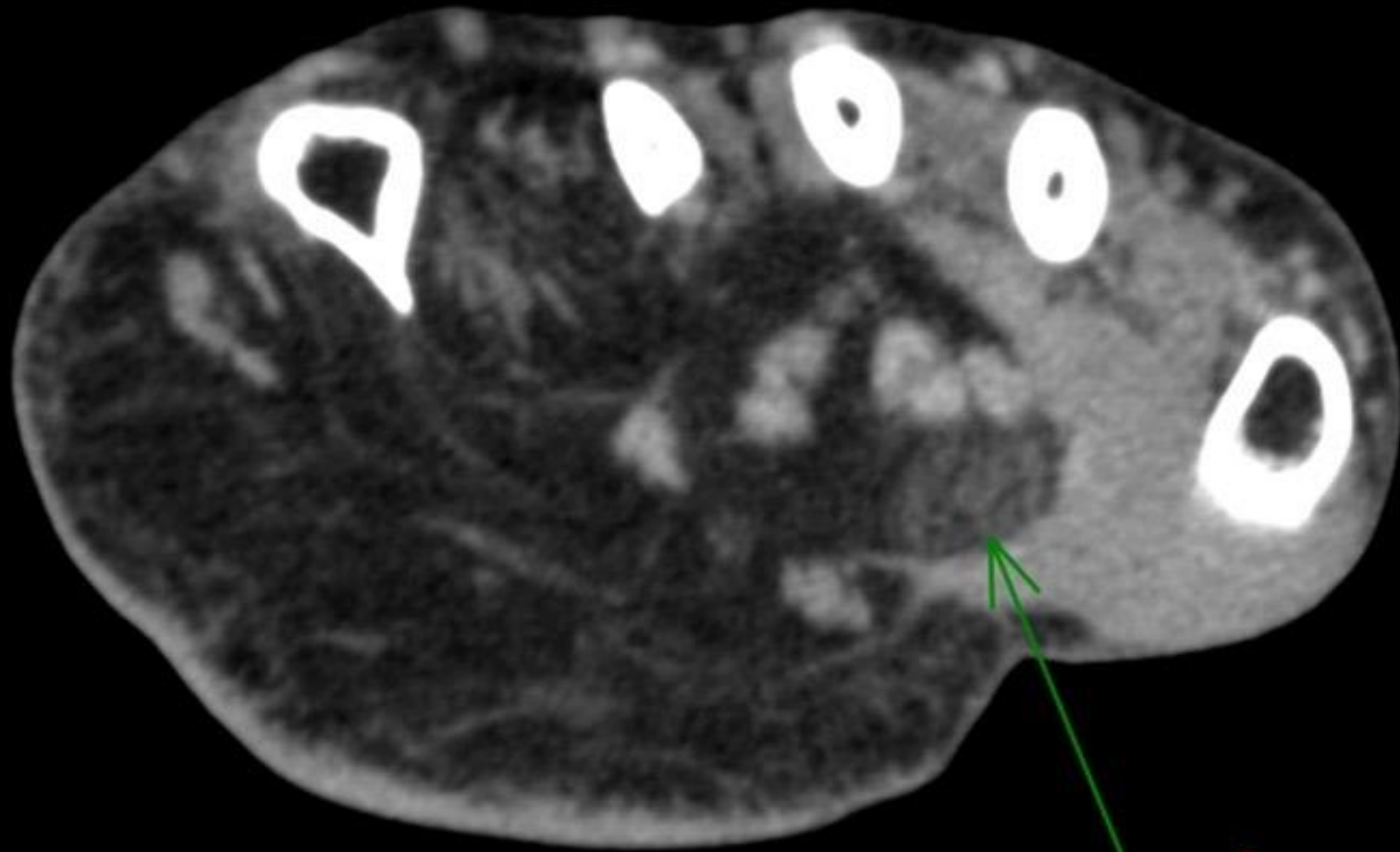
□ - proeminência do tecido adiposo na região adjacente



NERVO MEDIANO







NERVO MEDIANO

