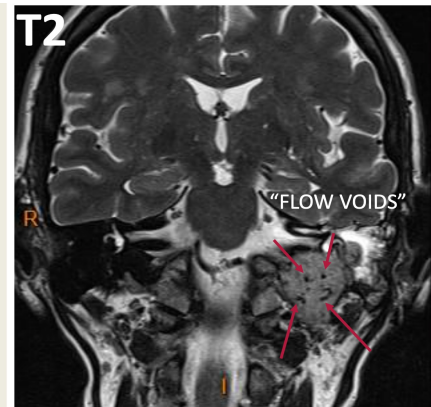
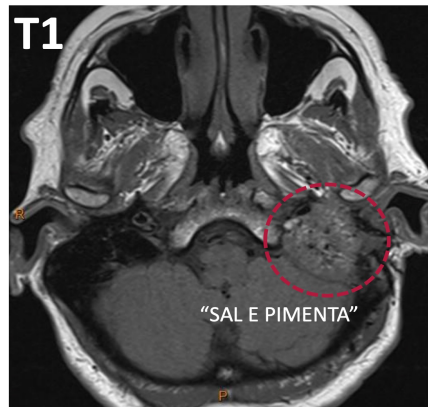
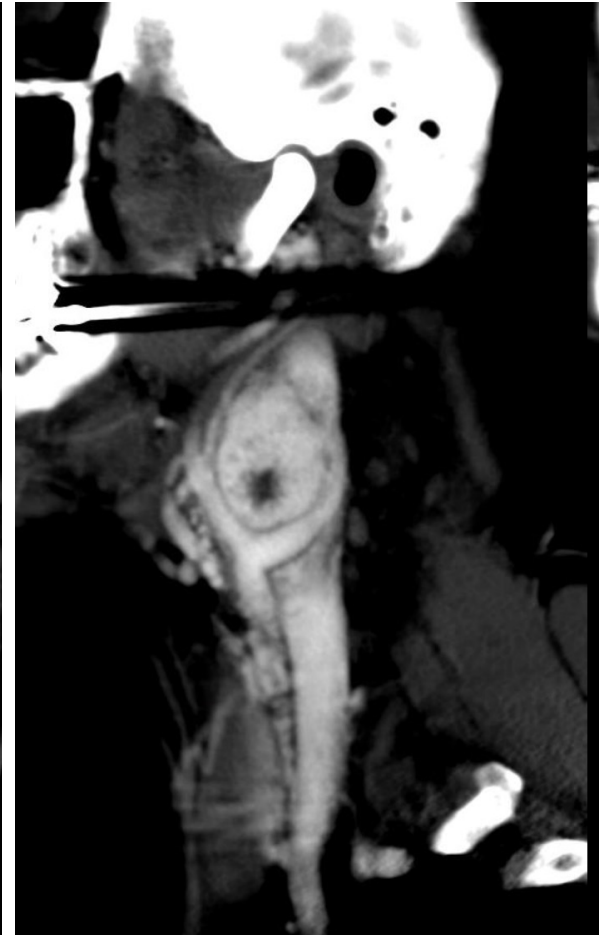
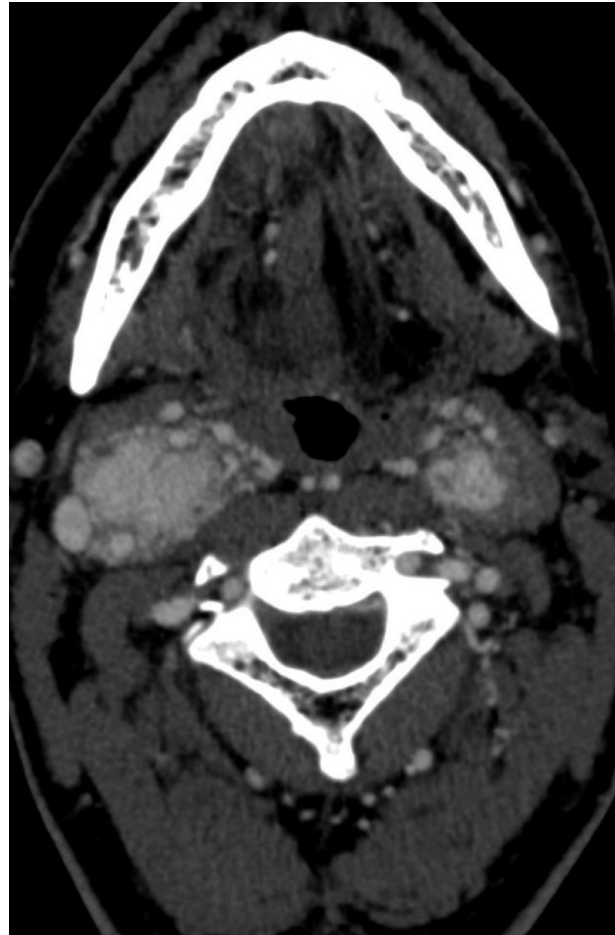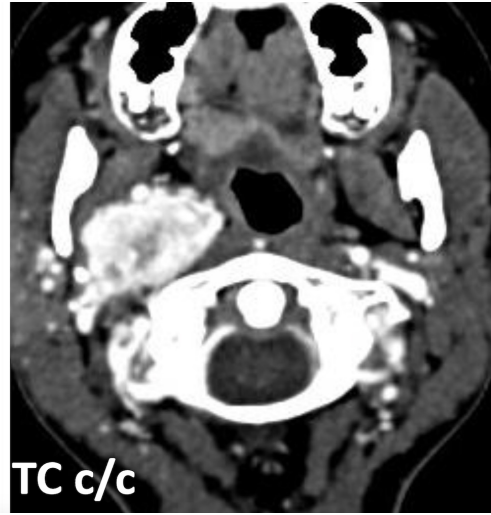
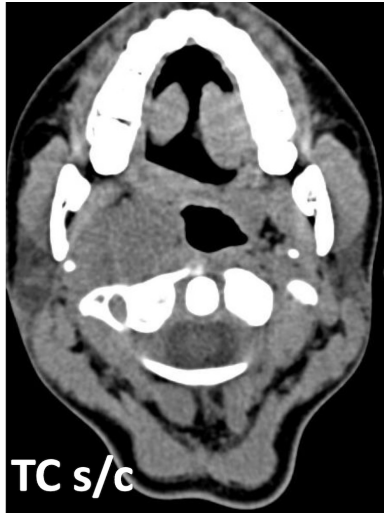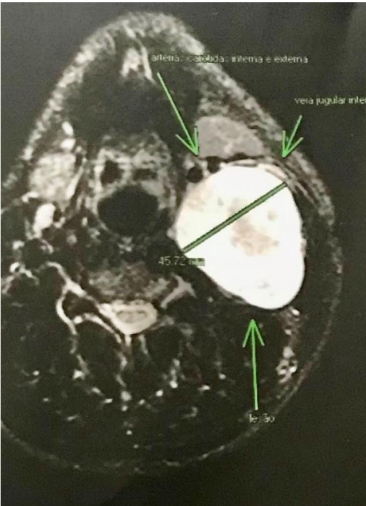
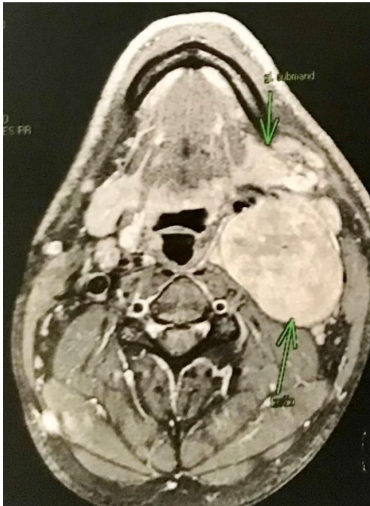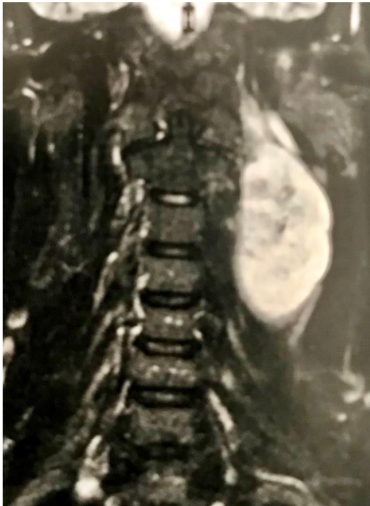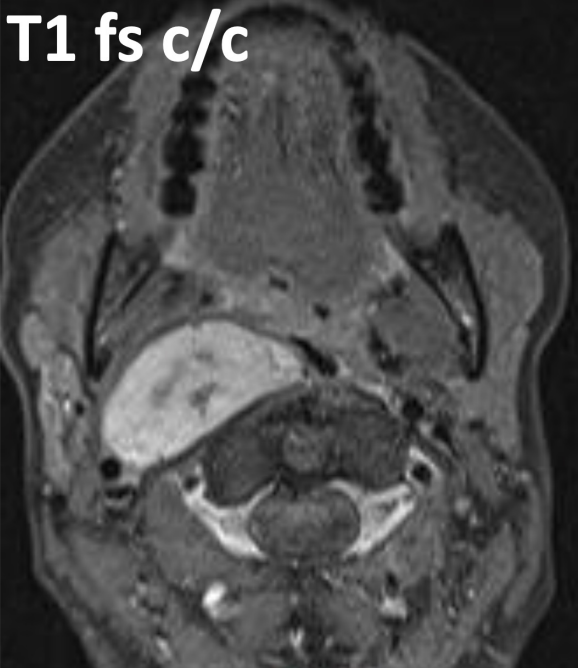
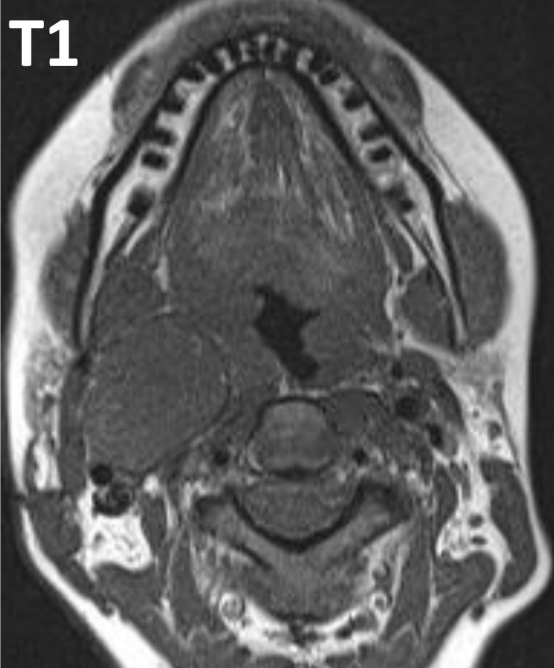


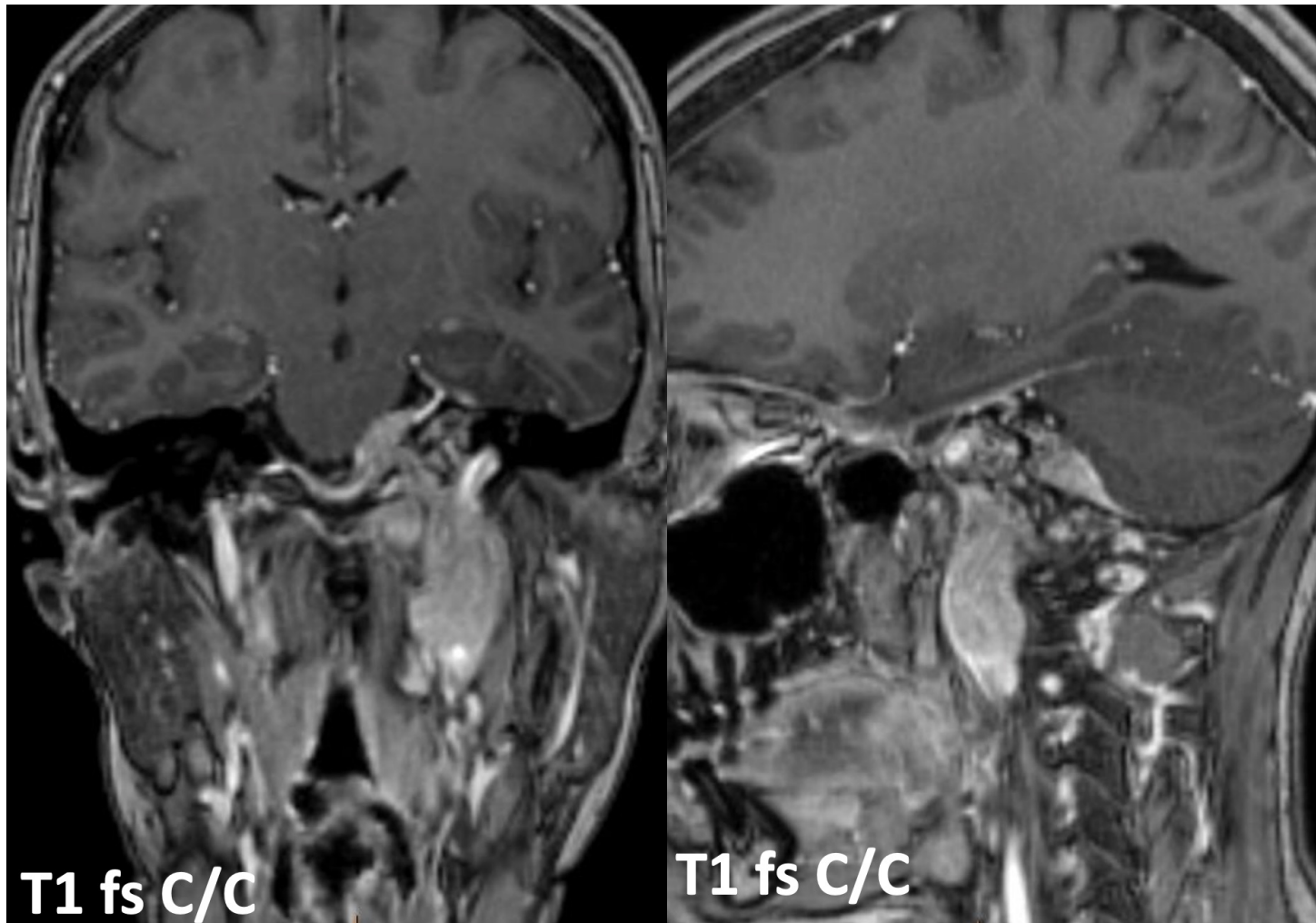
Paragangliomas



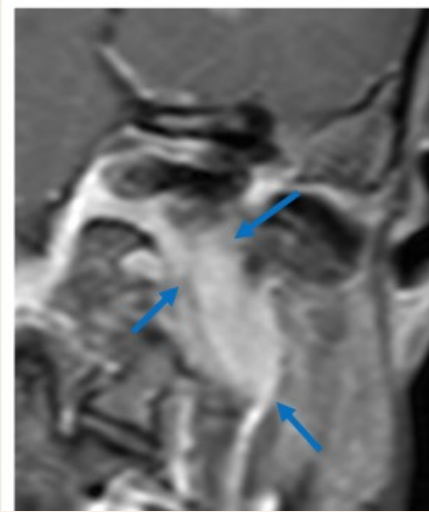
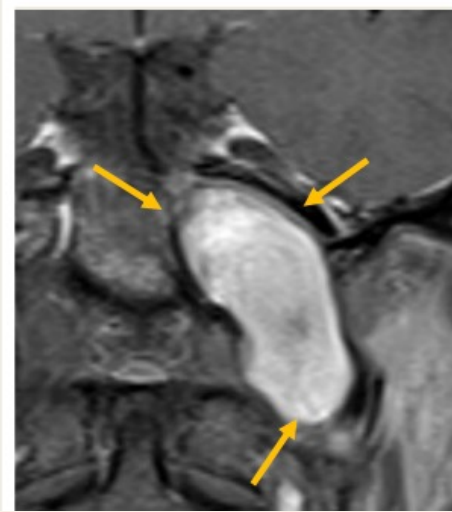
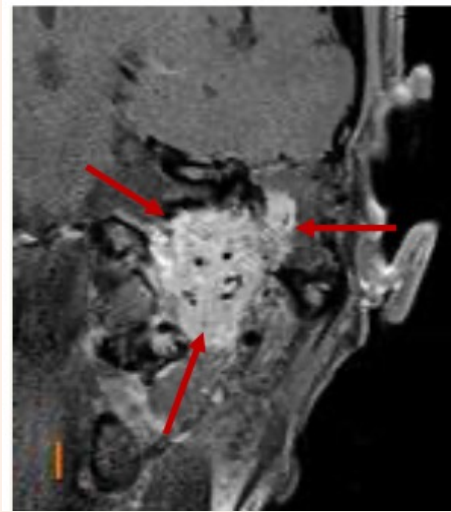
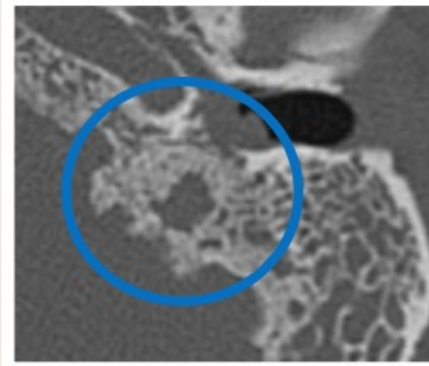
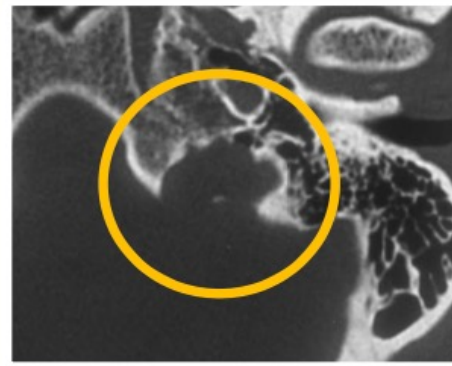
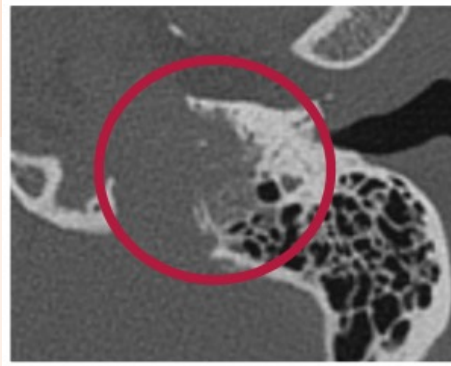
Tumor benigno de origem nervosa



Meningioma do espaço carotídeo



Diagnóstico diferencial



PARAGANGLIOMA

SCHAWANNOMA

MENINGIOMA

Correlação imagem-cirurgia

