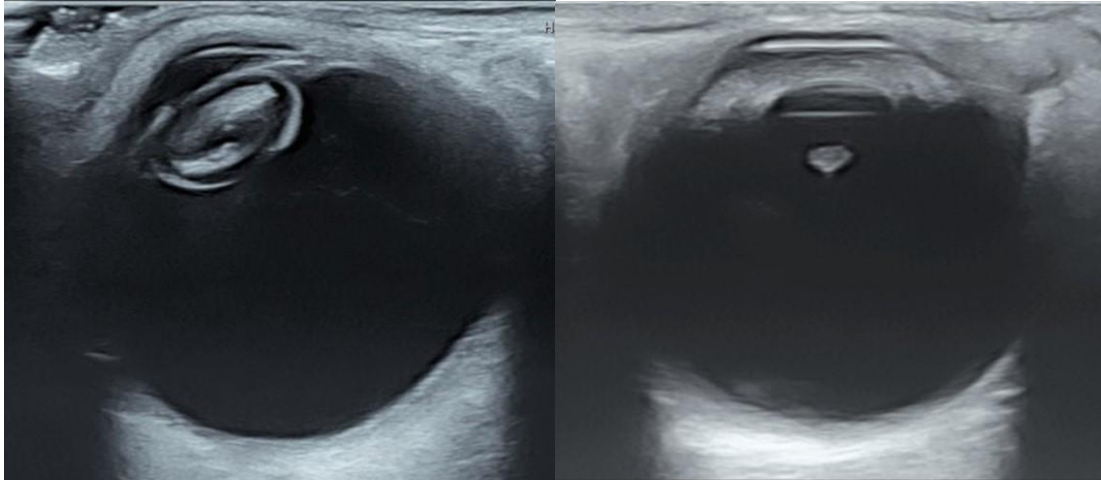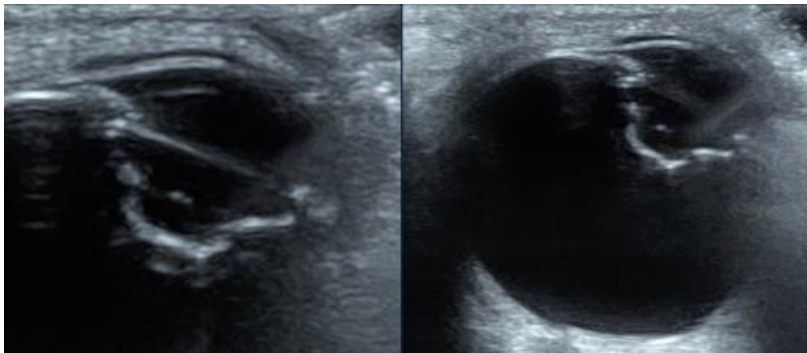
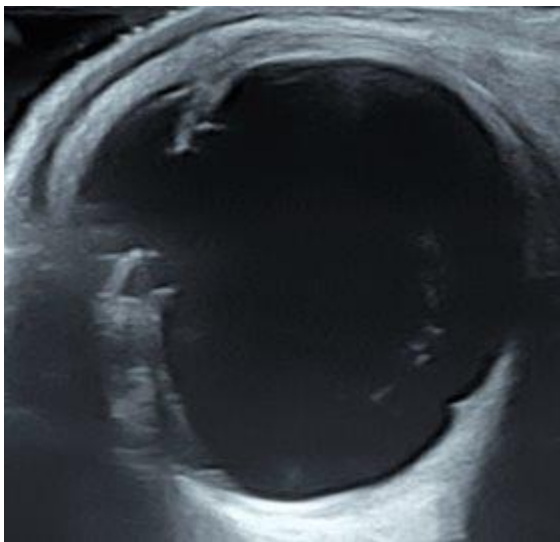


Left image: ocular cataract; right image: lenticono posterior



US lentiglobo



US; Afaquia