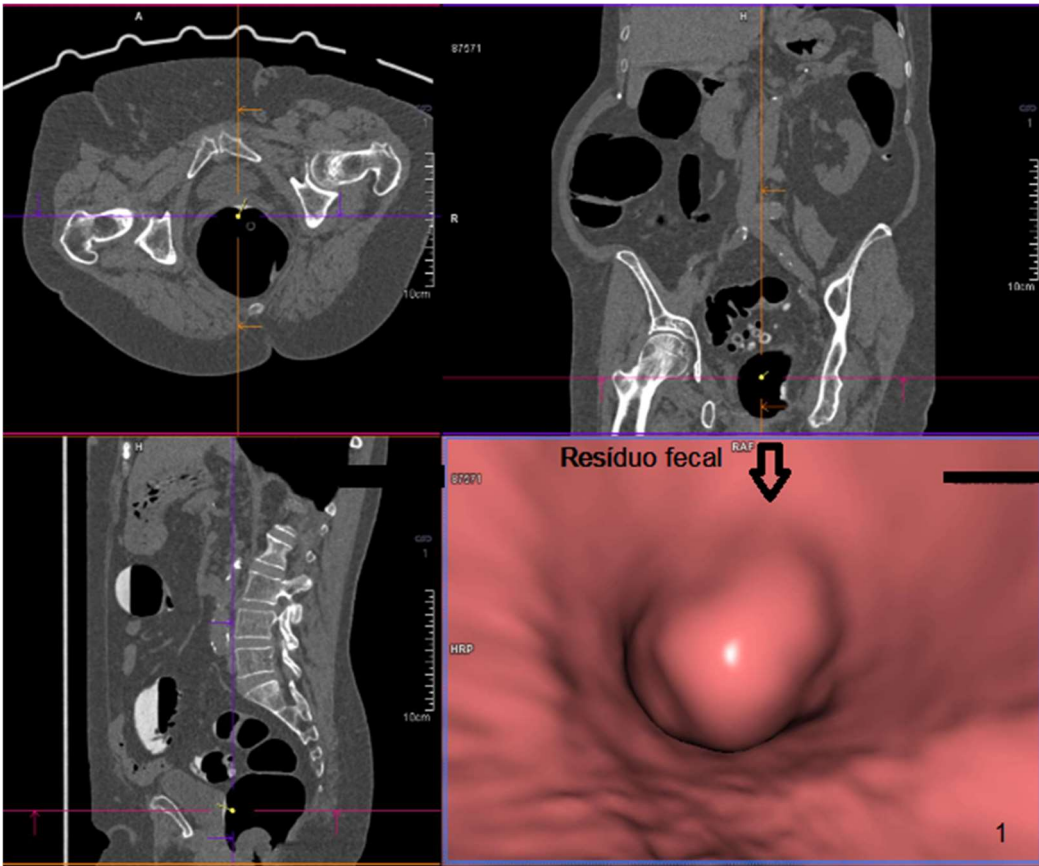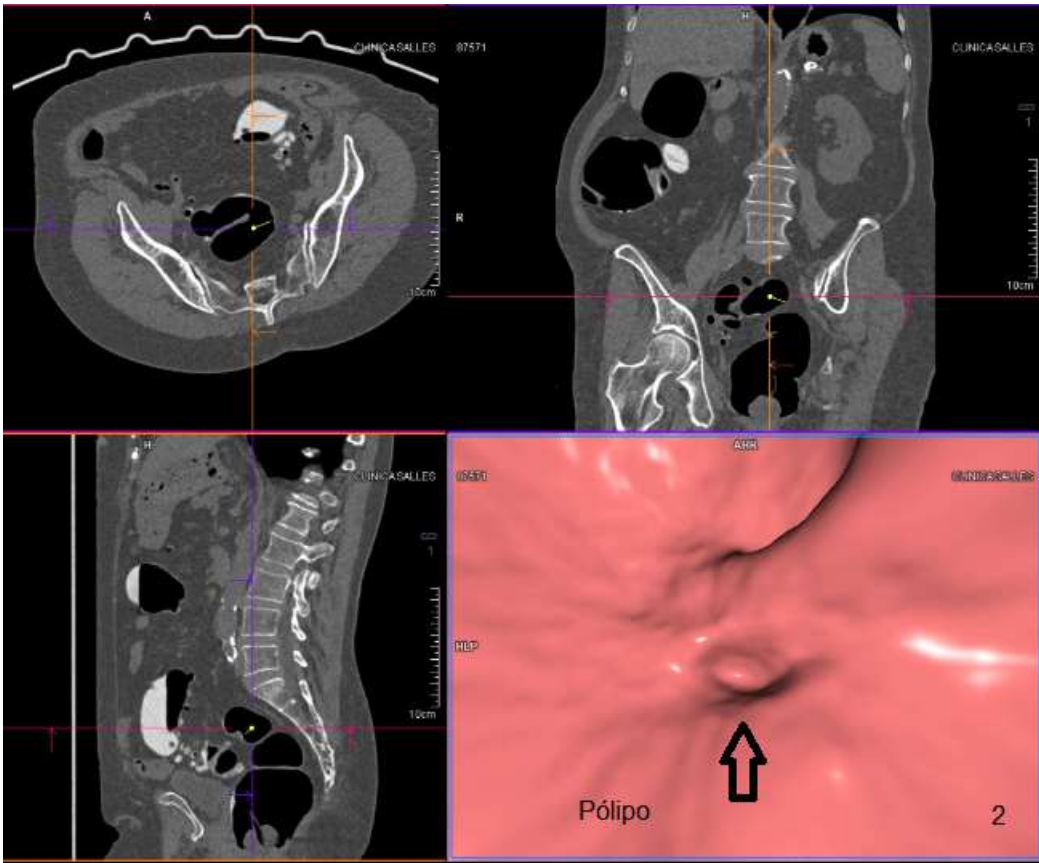
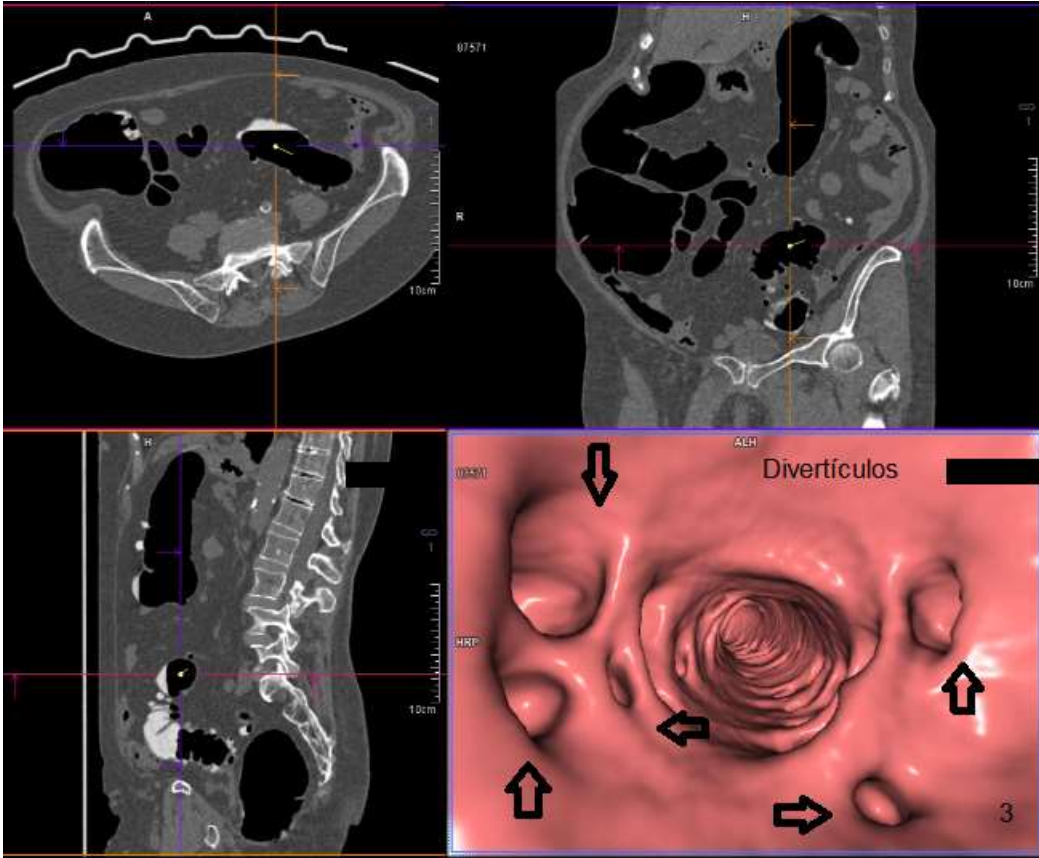


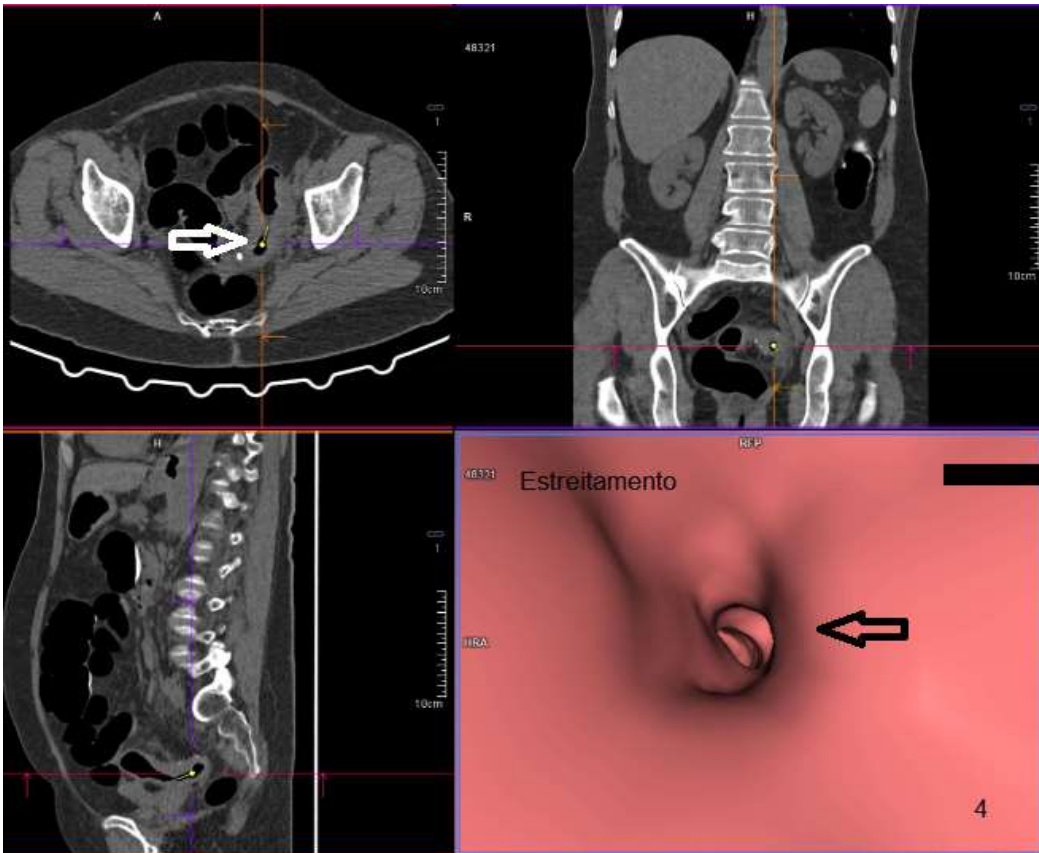
Resíduo fecal.



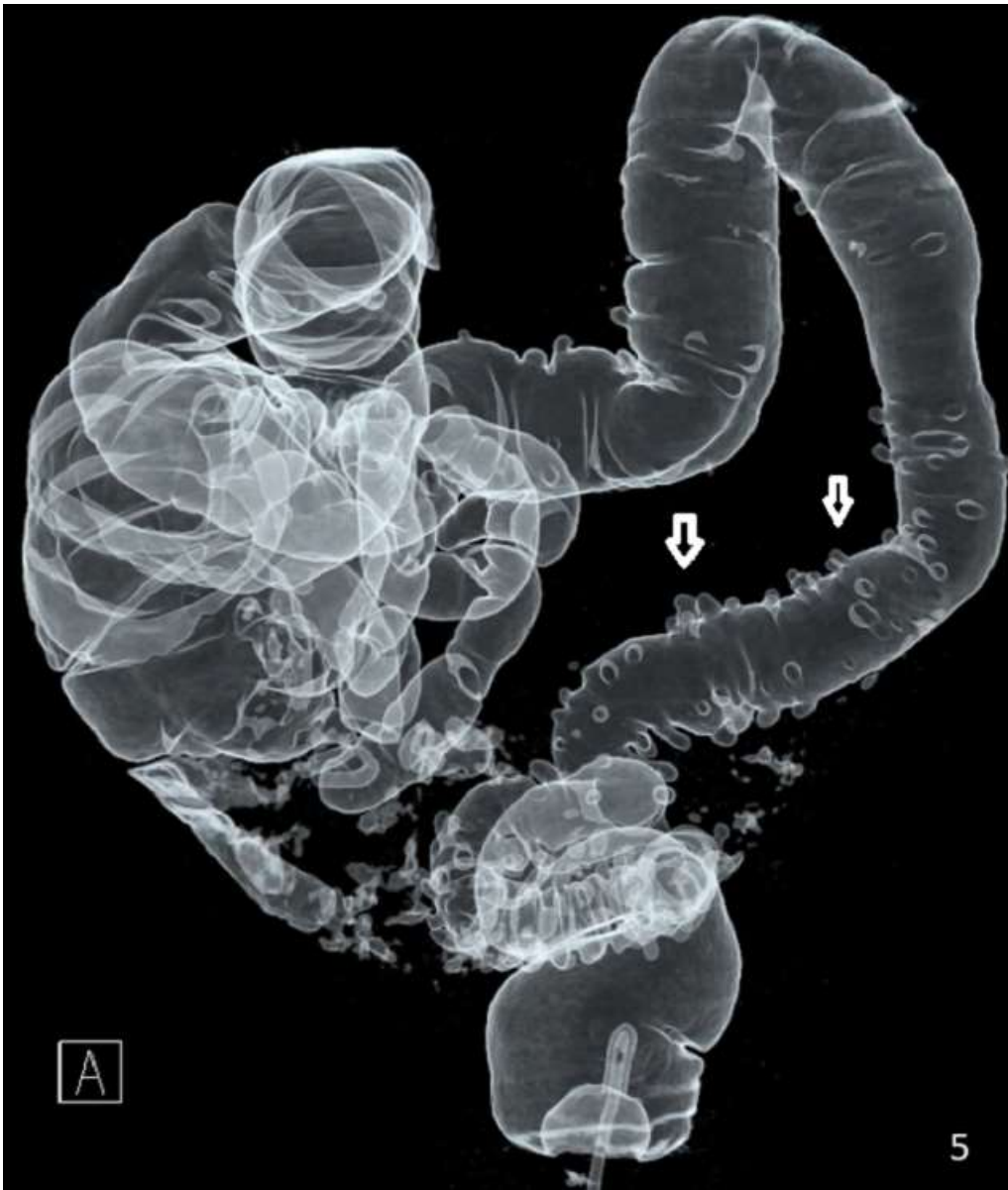
Pólipo em cólon sigmoide.



Divertículos em cólon sigmoide.



Estreitamento devido espessamento das paredes em cólon sigmoide.



Reconstrução VRT transparente. Sinalização em divertículos.