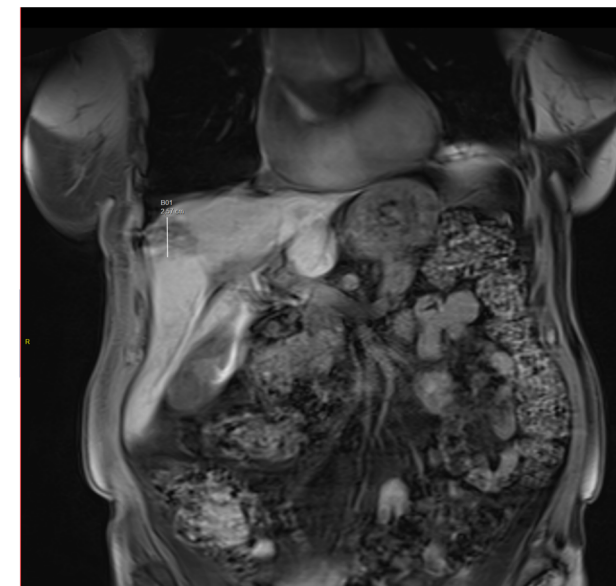
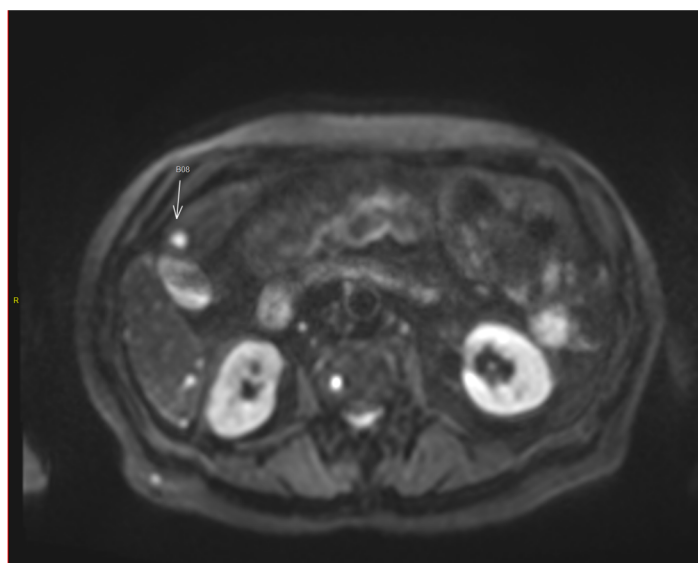
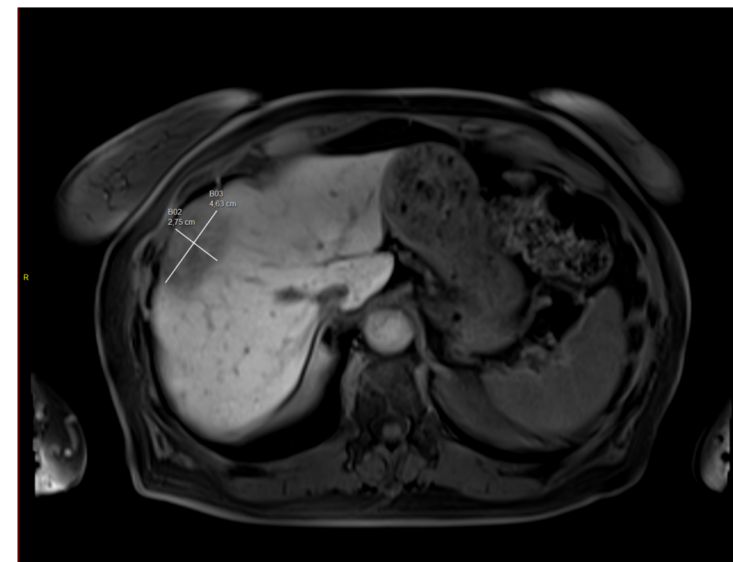
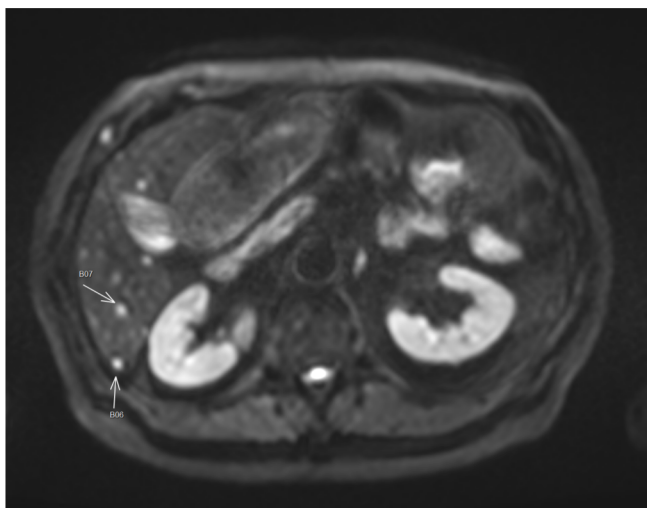
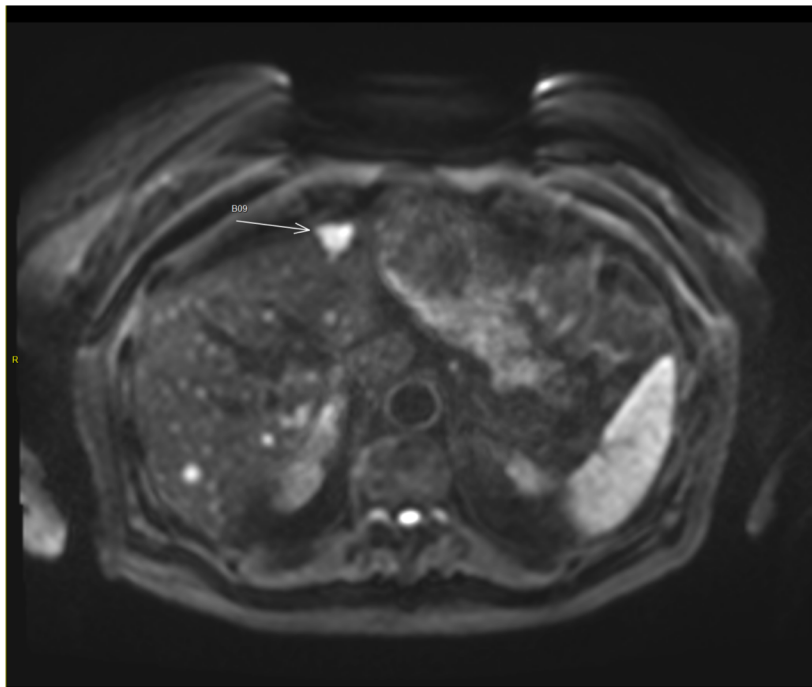


Feminina, 71 anos, melanoma uveal metastático para o fígado.
Comorbidades: hipotireoidismo, HAS e hipercolesterolemia

Ressonância magnética baseline 29/03/2023

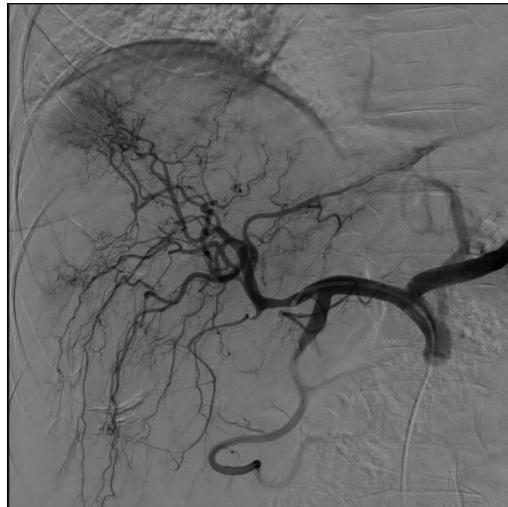

- Bilirrubinas total = 0,42 mg/dL
- Creatinina = 0,65
- Albumina = 3,8 g/dL

Etapa 1 – Angiografia, pesquisa do shunt hepatopulmonar e volumetrias

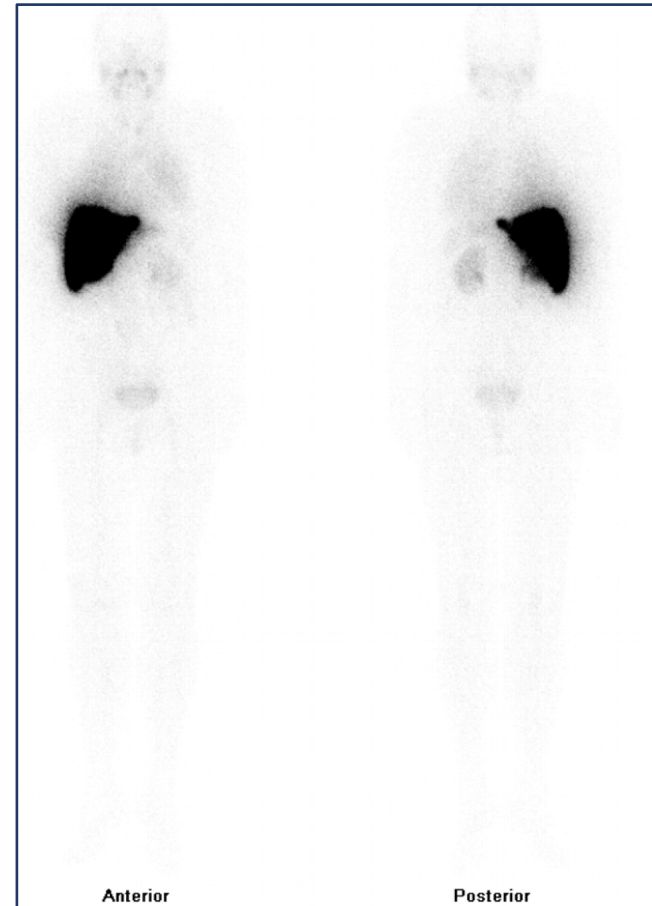
17/02/2023

Angiografia



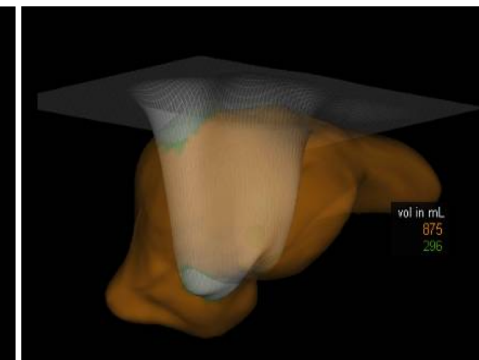
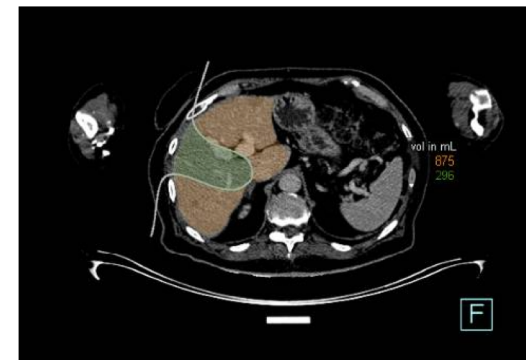
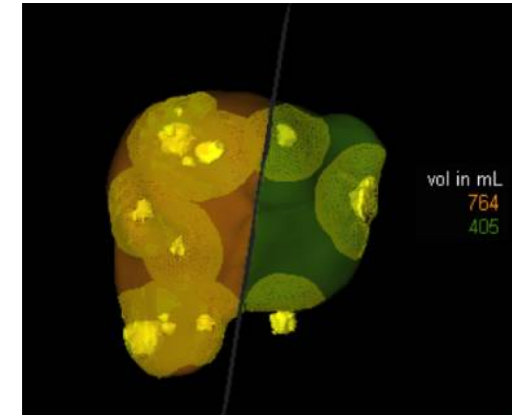
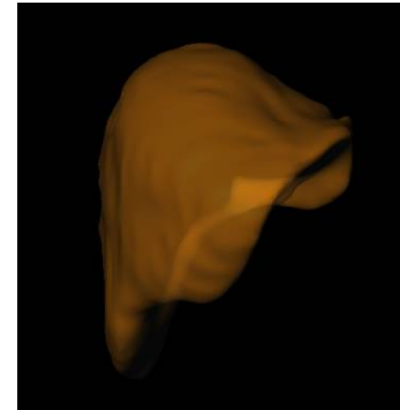
Lesões hipervasculares

Shunt hepatopulmonar = 5,7%



Cintilografia de corpo inteiro

Volumetrias

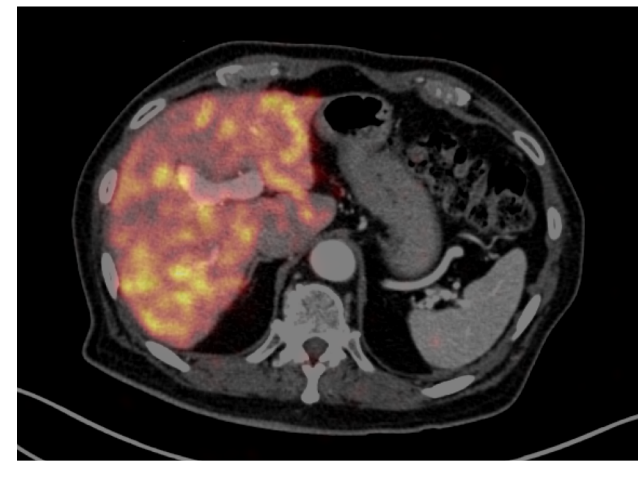
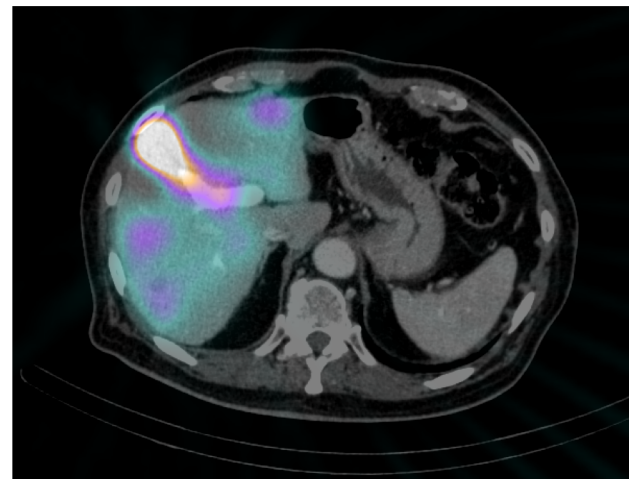
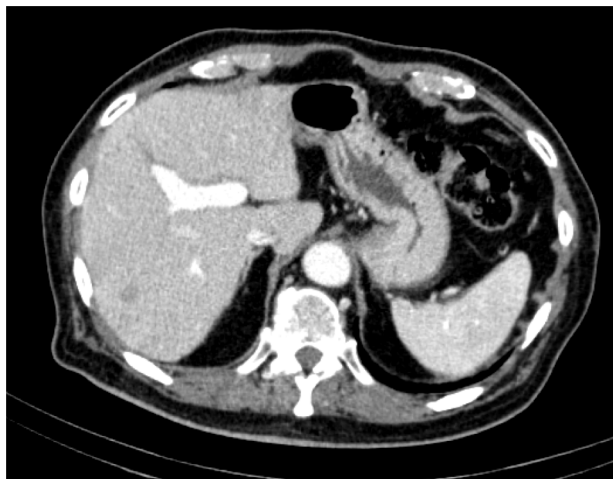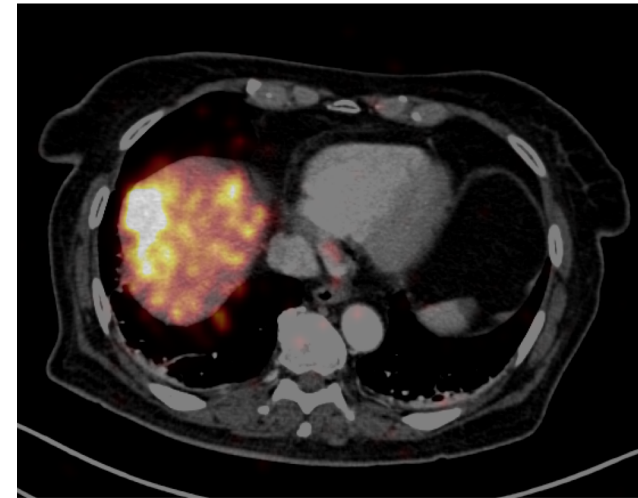
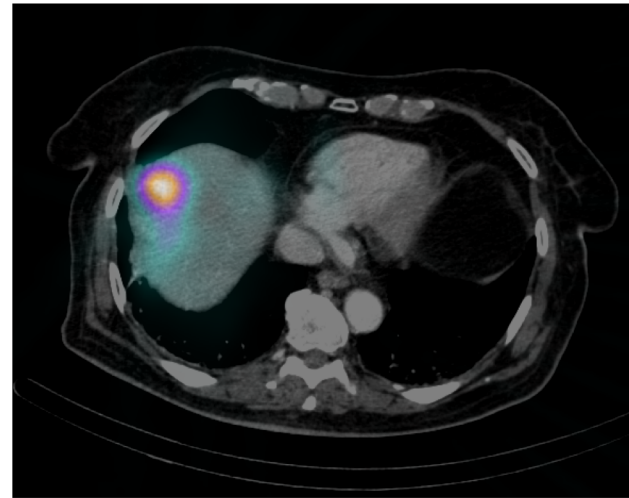
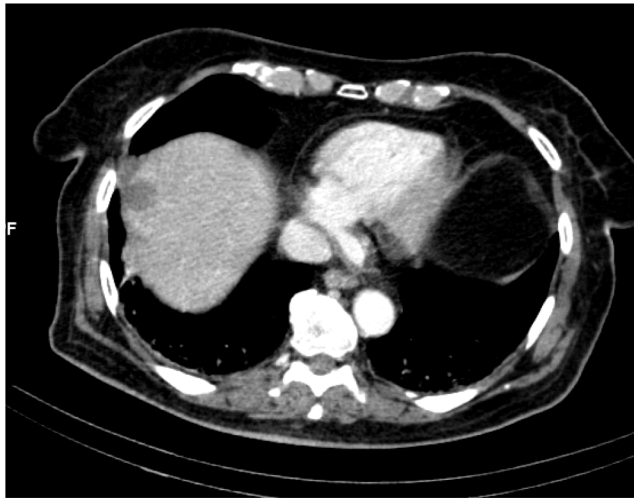


SPECT-CT para cálculo de volumetrias

Etapa 1 + Etapa 2

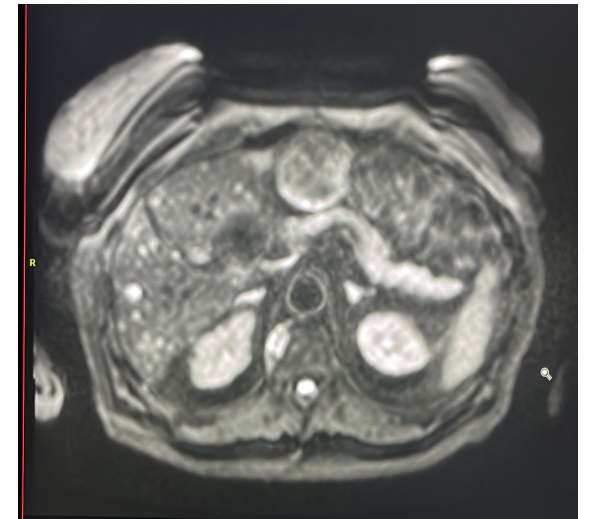
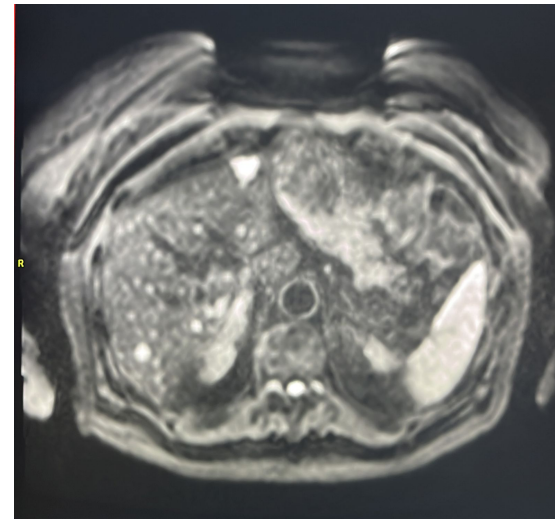
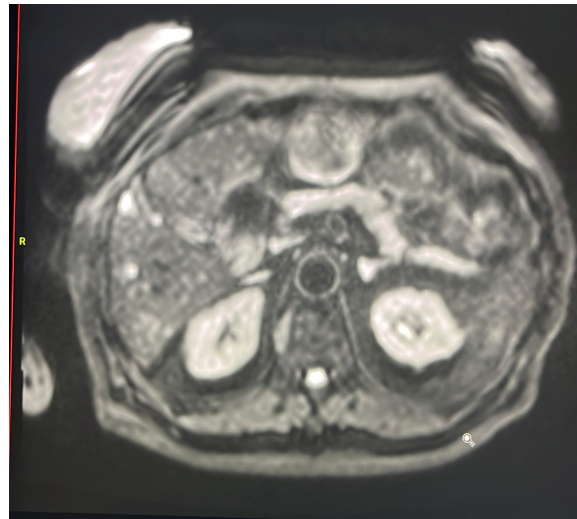
SPECT-CT 17/02/2023

PET-CT 31/03/2023



Resposta terapêutica

RM abdômen
15/02/2023
Pré-radioembolização



RM abdômen
18/07/2023
Pós-radioembolização

